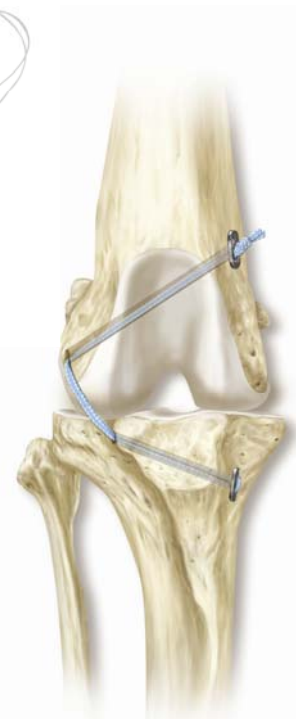

TightRope CCL Multi-Site Data Sheet

Cases Reported: 1,004 cases
 Duration: 3 mo. to > 3 yrs
 Weight Range: 2-93 kg
 Centers Reporting Data: 29



Reported Success Rate

93.9% Success rate

54.1% Full Function (restoration to, or maintenance of, full intended level and duration of activities and performance from pre-injury or pre-disease status without medication)

39.8% Acceptable Function (restoration to, or maintenance of, intended activities and performance from pre-injury or pre-disease status that is limited in level or duration and/or requires medication to achieve)

Complications

- 0% Catastrophic (resulting in permanent disability or death)
- 9.9% Major (requires further treatment based on current standard of care)
 - Subsequent Meniscal Tears – 4.0%
 - Implant/Technique Failures – 3.1%
 - Infection – 2.8%
- 10.1% Minor (not requiring additional surgical or medical treatment to resolve)

** reported complication rates for TPLO, lateral suture, TTA, and cranial closing wedge osteotomy range from 17-59% in the peer-reviewed veterinary literature*

Special thanks to the following centers and doctors for reporting their data.

- | | |
|--|---|
| ❖ Dr. Mark Albrecht – Gallatin Veterinary Hospital | ❖ Dr. Garren Kelly – Byron Pet Clinic |
| ❖ Dr. Jeff Baker – Crawford Animal Hospital | ❖ Dr. David Kydd – Kydd Veterinary Health Centre of London |
| ❖ Dr. Toni Barnes – Westside Veterinary Clinic | ❖ Dr. Tom Liebl – Clinton Parkway Animal Hospital |
| ❖ Dr. Bert Blackburn – Buck Animal Hospital | ❖ Dr. Julius Liptak – Alta Vista Animal Hospital |
| ❖ Dr. Cal Cadmus – Oakdale Veterinary Group | ❖ Dr. Thomas McNicholas – Affiliated Veterinary Specialists |
| ❖ Dr. Jimi Cook – University of Missouri | ❖ Dr. Paul Newman – Mobile Veterinary Surgical Services |
| ❖ Dr. Robert Cook - Animal Medical Center of St. Charles | ❖ Dr. Frank Odgen – Bonita Springs Veterinary Hospital |
| ❖ Dr. David Crouch – Western Carolina Veterinary Surgery | ❖ Dr. Antonio Pozzi – University of Florida |
| ❖ Dr. Chad Devitt – Veterinary Referral Center of Colorado | ❖ Dr. Charles Pullen – Animal Medical and Surgical Center of Arizona |
| ❖ Dr. Felix Duerr – Aspen Meadows Veterinary Specialists | ❖ Dr. Matt Rooney – Aspen Meadows Veterinary Specialists |
| ❖ Dr. Jay Erne – Affiliated Veterinary Specialists | ❖ Dr. Jeff Schuett – Pewaukee Veterinary Services |
| ❖ Dr. Mike Ferber – North Shore Animal Hospital | ❖ Dr. Abbie Tipler – Kydd Veterinary Health Centre of London |
| ❖ Dr. Garrett – Animal Hospital of Fayetteville | ❖ Dr. Peter Veling – Caring Hands Pet Hospital |
| ❖ Dr. Mitch Gillick – Toronto Veterinary Emergency Hosp | ❖ Dr. Arathi Vinayak - Arlington Veterinary Surgery Specialist |
| ❖ Dr. Peter Haase – Arlington Veterinary Surg. Spec. | ❖ Dr. Ned Williams – Eastern Carolina Veterinary Referral Animal Hospital |
| ❖ Dr. Craig Hook – Mid-Michigan Veterinary Referral Center | ❖ Dr. Will Wright – Capitol Illini Veterinary Services |
| ❖ Dr. Nick Kalafatic – Meridian Veterinary Hospital | |

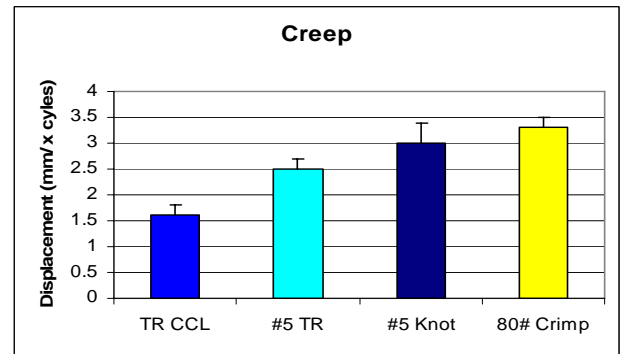
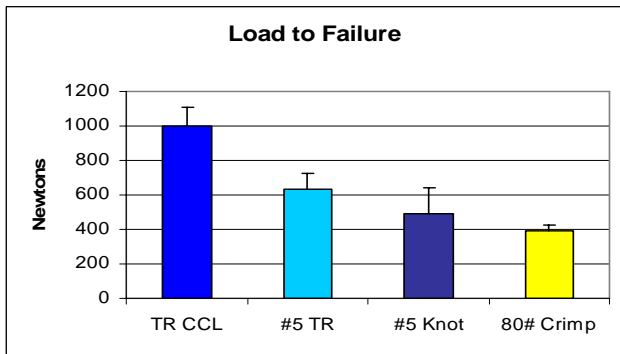
Advantages of TightRope CCL

- Bone to Bone fixation
- Helps ensure isometric implant placement
- Allows for minimally invasive technique
- Strength and Stiffness of Fibertape
- Low profile Implant with good handling
- Potential for addressing all abnormal forces

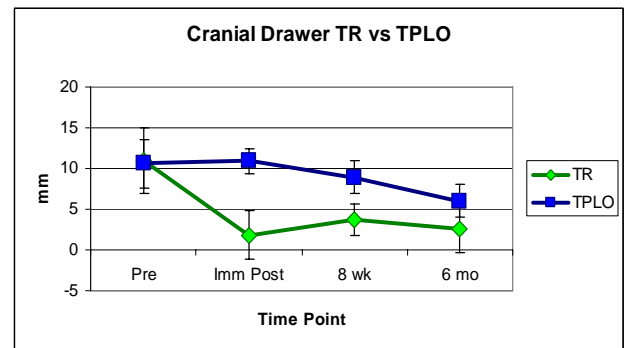
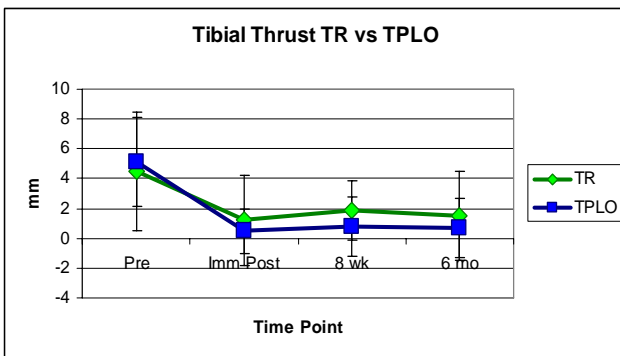
Potential Contraindications for TightRope CCL

- Tibial Plateau Angle > 32 degrees
- Angular Limb Deformity
- Connective tissue healing abnormalities
- Condyle < 12mm cranial to caudal
- Poor postop compliance

Biomechanical Testing Data



Subjectively measured stifle stability for TightRope (TR) vs TPLO



Client-based Outcomes Assessments for TightRope (TR) vs TPLO at 6 months after surgery

